

Original article

Clinical outcomes of spinal schwannoma microsurgery

Nattawut Niljianskul*

Department of Surgery, Faculty of Medicine Vajira Hospital, Navamindradhiraj University,
Dusit, Bangkok 10300, Thailand

Background: Gross total resection of solitary spinal schwannomas (SS) and preservation of neurological functions are the gold standard of treatment for symptomatic patients; however, some patients present with postoperative neurological deficit.

Objective: This study aimed to evaluate the neurological outcomes of SS microsurgery and identify the risk factors of postoperative neurological deficit among patients at the Vajira Hospital.

Methods: The following preoperative and postoperative neurological outcome measurements were reviewed at 1, 6, and 12 months according to the following procedure: Frankel Grading, McCormick Score, American Spinal Injury Association Grading, Karnofsky Performance Status Scale, and Japanese Orthopedic Association Score. The predictive values of various clinical factors were assessed.

Results: Fifty patients (mean age, 49.0 ± 16.3 years) underwent the surgery, and 79.6% of them presented with pain. The tumors were located in the thoracic (27.3%), cervical (22.7%), and cauda equina (20.5%) regions. Most tumors were intradural/extramedullary (81.8%). A statistically significant improvement between the preoperative and postoperative neurological outcomes was observed ($P < 0.05$). Intraoperative blood loss (odds ratio [OR], 1.007; 95% confidence interval [CI], 1.001 - 1.013; $P = 0.026$) and operative time (OR, 2.629; 95% CI, 1.164 - 5.936; $P = 0.02$) were associated with postoperative neurological deficit.

Conclusion: SS may occur at any levels in the spine and is typically intradural in location. Treatment with microsurgery significantly improved the postoperative neurological outcomes of the patients. However, intraoperative blood loss and operative time are the risk factors associated with the occurrence of postoperative neurological deficits.

Keywords: Microsurgery, neurological outcomes, risk factors, spinal schwannoma.

Primary spinal tumors account for approximately 4.0% - 8.0% of all central nervous system tumors, and tumors of the nerve sheath account for up to 30.0% of the spinal tumors; solitary spinal schwannomas (SS) are the most common nerve sheath tumors in the spine.^(1,2) They occur equally in men and women with the peak of prevalence during the fourth and fifth decades of life.⁽³⁻⁷⁾ Most SS appear as solitary tumors and can occur throughout the spinal canal. They normally arise from Schwann cells in the dorsal nerve roots and are located at the dorsolateral part of the spinal cord, but sometimes, they can arise from the ventral nerve roots. In addition, they tend to occur as intradural lesions, but in some instances, they may

occur as dumbbell tumors. Several studies reported that up to 80.0% of all SS located intradural/extramedullary lesions, and approximately 15.0% appeared as a dumbbell-shaped mass with both intra- and extradural lesions.^(8,9)

SS appears as a well-encapsulated benign tumor that displaces the nerve roots and separates from them. These tumors are nearly always treated using the standard posterior midline approach; a more extensive approach is required in only a few cases. Gross total resection (GTR) of the tumor and preservation of the neurological functions are the gold standard of treatment for symptomatic patients. Although several studies have reported good outcomes following surgery, some cases have presented with postoperative neurological deficit. Emel E, *et al.* reported that GTR was achieved in 83.7% of the patients, worsening postoperative neurological outcome was found in 10.1% of the patients, and the most common postoperative complication was surgical site infection.⁽⁸⁾

*Correspondence to: Nattawut Niljianskul, Department of Surgery, Faculty of Medicine Vajira Hospital, Navamindradhiraj University, Dusit, Bangkok 10300, Thailand.

E-mail: nattawut@nmu.ac.th

Received: February 16, 2022

Revised: November 15, 2022

Accepted: December 3, 2022

This study aimed to evaluate the clinical presentation and neurological outcome within 12 months after surgical resection and identify the risk factors that potentially affect the postoperative neurological outcomes in patients with SS.

Materials and methods

This study has been approved by the Ethics Committee, Vajira Hospital (191/64E). All patients who were newly diagnosed with SS and underwent microsurgery at the Vajira Center of Excellence in Neurosurgery between January 2010 and December 2020 were recruited in the study. Patients diagnosed with neurofibromatosis (NF) I and II, neurofibroma, or malignant nerve sheath tumors were excluded. Demographic data pertaining to the age, gender, body mass index (BMI), clinical presentation, length of stay, underlying disease, localization and location of the tumor, tumor size, duration of symptoms, types of operation, extent of resection, operative time, blood loss, recurrent of disease, and postoperative complications were collected. The records of the patients were reviewed for the following preoperative neurological outcomes at 1, 6, and 12 months after the operation: Frankel Grading, McCormick Score, American Spinal Injury Association (ASIA) Grading, Karnofsky Performance Status (KPS) Scale, and Japanese Orthopedic Association (JOA) Score. In addition, the following postoperative neurological outcomes were reviewed. Poor neurological outcome in this cohort was defined as a worsening of postoperative indicators (Frankel Grading, McCormick Score, ASIA Grading, KPS Scale, and JOA Score) compared to preoperatively. All patients underwent magnetic resonance imaging of the spine with contrast for the preoperative and postoperative (1 year after surgery) evaluations. All the tumors that were surgically excised underwent histopathological examinations with hematoxylin-eosin staining by pathologists to confirm the diagnosis of SS.

Surgical technique

All patients underwent a standard midline posterior approach for tumor resection under an operative microscope, and microsurgical instrumentation was used in most cases; the posterolateral or far lateral approach was used in cases where the tumor was located in the craniocervical region (C0 - C2). Intraoperative neurophysiological monitoring (IONM)

was used for the majority of the patients, depending on the availability of equipment on the day of surgery. Gross total resection (GTR) of the tumor was attempted on all patients and nerve cutting was considered in all the thoracic and ventral nerve root originated tumors to minimize the effects on the quality of life of the patient after the operation. If the dorsal root is suspected from macroscopic or IONM, the nerve root is left in place. Every effort was made to prevent postoperative instability. Posterior fixation was performed in the following instances: more than half of the facet joints were removed for total tumor resection, vertebral body erosion, tumors located at the cervicothoracic junction, and concomitant unstable spine fracture. As for the dura closure, 6 - 0 Prolene using the continuous locking watertight suture technique was performed and the Valsalva maneuver was used to test for leakage. On the other hand, tears in the dura that cannot be sutured, such as those in the dural sleeve, were treated by placing fat within the leakage areas and locally injecting fibrin glue. The leakage was tested using the Valsalva maneuver, and a low-pressure drain with a tight suture muscle sheath was placed if no further leakage was observed.

Statistical analysis

Statistical analysis was performed using the Stata 13.0 software (StataCorp, College Station, TX, USA). The paired *t* - test was used to compare continuous variables. The data are presented as mean \pm standard deviation (SD). The preoperative and postoperative neurological outcome parameters (Frankel Grading, McCormick Score, ASIA Grading, KPS Scale, and JOA Score) were compared by repeated measures analysis of variance (ANOVA). Univariate logistic regression was performed to assess the association between each neurological outcome parameter. A multivariate logistic regression model was used to adjust the predictions that affected the neurological outcome parameters. A $P < 0.05$ was considered as statistically significant.

Results

Patient demographics

Four patients diagnosed with neurofibroma and two patients diagnosed with malignant nerve sheath tumors were excluded from the study. Finally, 44 patients (males, 22; females, 22) without necrotizing fasciitis (NF) who underwent surgery for SS were included. The mean age of the patients was $49.0 \pm$

16.3 years, and the mean BMI was 24.0 ± 4.5 kg/m². Pain was the most common symptom followed by sensory disturbances. Motor weakness was present in more than half of the patients. Only one patient was asymptomatic. Most tumors were intradural/extramedullary (IDEM) followed by extradural and dumbbell tumors. No intramedullary SS tumor was observed in this cohort. The anatomical location in terms of the dural relationship and tumor level along the spinal axis is shown in Table 1. Most of the tumors were located in the thoracic spine (n = 12; 27.3%), followed by the cervical (n = 10; 22.7%), cauda equina (n = 9; 20.5%), and craniocervical (n = 7; 15.9%) regions. GTR was achieved in 39 (88.6%) of the 44 lesions. Only subtotal resection (STR) could be achieved in five patients (11.4%; one extradural cervical lesion [C5], two intradural cervical [C5] lesions, and two intradural thoracic lesions [T12 - L1]) to avoid injury to the brachial plexus and conus medullaris. Three patients with STR experienced tumor recurrence during the follow-up period.

A conventional laminectomy, laminotomy, or hemilaminectomy was sufficient for the treatment of most lesions. The far lateral approach was used in some patients (n = 5; 11.4%) with craniocervical SS. Three patients with total facetectomy, one with costro-transversectomy, three with thoracolumbar junction tumors, two with cervicothoracic junction tumors, and one with a concomitant vertebral burst fracture underwent posterior fixation after tumor removal. IONM was used in approximately 79.6% (n = 35) of the tumors. The mean values for the tumor size, duration of symptoms, operative time, and blood loss were 27.0 ± 15.2 mm, 10.0 ± 16.1 months, 5.0 ± 1.7 h, and 250.0 ± 159.2 ml, respectively. Infection of the surgical site was the most common (n = 2; 4.6%) postoperative complication. As shown in Table 2 and Figure 1, statistically significant ($P < 0.05$) differences were observed between the preoperative and postoperative neurological outcome measurements during the follow-up period.

Table 1. Characteristics of patients.

Characteristics	Total (n = 44)
Gender	
Male	22 (50.0)
Female	22 (50.0)
Age, years	49.0 ± 16.3
Body mass index (kilogram/meter ²)	24.0 ± 4.5
Length of stay (day)	11.0 ± 5.9
Clinical presentation	
Asymptomatic	1 (2.3)
Pain	35 (79.6)
Motor	28 (63.6)
Sensory	30 (68.2)
Gait disturbance	5 (11.4)
Bowel/bladder symptoms	11 (25.0)
Localization	
Extradural	4 (9.1)
Intradural/extramedullary	36 (81.8)
Dumbbell	4 (9.1)
Anatomical location	
C0 - 2	7 (15.9)
C3 - 7	10 (22.7)
C7 - T1	2 (4.6)
T2 - T11	12 (27.3)
T12 - L1	3 (6.8)
Conus	1 (2.3)
Cauda	9 (20.5)
Extent of resection	
Gross total resection	39 (88.6)
Subtotal resection	5 (11.4)

Table 1. (Cont.) Characteristics of patients.

Characteristics	Total (n = 44)
Tumor location	
Ventral	8 (18.2)
Dorsal	15 (34.1)
Lateral	17 (38.6)
Dumbbell	4 (9.1)
Intraoperative neurophysiology monitoring	
Yes	35 (79.6)
No	9 (20.5)
Underlying disease	
Osteoporosis	1 (2.3)
Type 2 diabetes	9 (20.5)
Hypertension	15 (34.1)
Coronary heart disease	2 (4.6)
Other	13 (29.6)
Tumor size, mm	27.0 ± 15.2
Number of levels	
1	30 (68.2)
2	9 (20.5)
>2	5 (11.4)
Duration of symptom, month	10.0 ± 16.1
Recurrence	3 (6.8)
Operative time, hour	5.0 ± 1.71
Blood loss (milliliter)	250.0 ± 159.2
Postoperative complication	
Surgical site infection	2 (4.6)
Cerebrospinal fluid leakage	1 (2.3)
Epidural hematoma	1 (2.3)
Other	1 (2.3)
None	39 (88.6)
Operation tumor removal	
Laminotomy	2 (4.6)
Laminectomy	27 (61.4)
Hemilaminectomy	9 (20.5)
Sacrificed nerve root	3 (6.8)
Partial facetectomy	2 (4.6)
Total facetectomy	3 (6.8)
Costrotransversectomy	1 (2.3)
Far lateral approach	5 (11.4)
Instrument	
Yes	10 (22.7)
No	34 (77.3)

Table 2. Neurological outcomes of patients compare between pre- and post-operation.

Outcomes	Pre-operation	Post-operation 1 month	Post-operation 6 months	Post-operation 12 months	P-value within groups
Frankel grade	3.9±0.7	4.3±0.6	4.8±0.4	4.9±0.2	<0.001
JOA score	13.7±3.5	16.1±2.3	17.3±1.7	17.8±0.7	<0.001
ASIA	3.9±0.7	4.3±0.6	4.8±0.4	4.9±0.2	<0.001
McCormick score	2.4±1.0	1.7±0.8	1.2±0.5	1.1±0.2	<0.001
KPS scale	70.2±16.4	84.0±14.0	93.2±11.7	97.9±5.4	<0.001

Values are presented as mean ± standard deviation

JOA, Japanese Orthopedic Association; ASIA, American Spinal Injury Association;

KPS, Karnofsky Performance Status

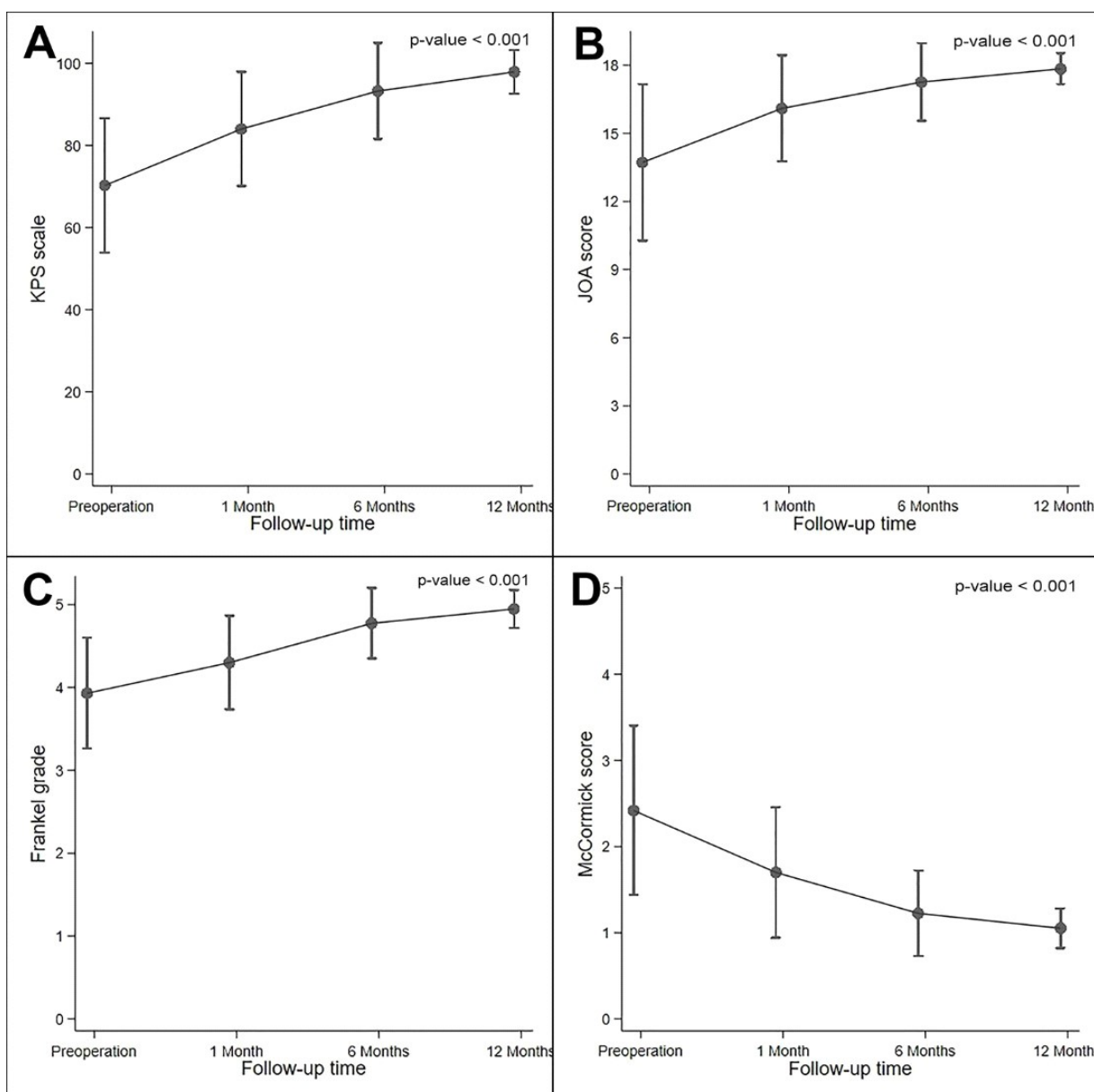


Figure 1. Preoperative and postoperative neurological outcome measurements at 1, 6, 12 months after operation, A) Karnofsky Performance Status (KPS) Scale, B). The Japanese Orthopedic Association (JOA) Score, C) Frankel Grade, D) McCormick Score.

The results of the multiple logistic regression analysis for neurological deficits are shown in Table 3. The operative time (odds ratio [OR], 2.629; 95% confidence interval [CI], 1.164 – 5.936; $P=0.020$), intraoperative blood loss (OR, 1.007; 95% CI, 1.001 – 1.013; $P=0.026$), and blood transfusion (OR, 14.400; 95% CI, 1.001 – 1.013; $P=0.026$) were found associated with poor neurological outcome. A 4.2-h-long surgery time was 2.6 times more likely to develop a postoperative neurological deficit. Patients who lost 200 mL of blood were 1.0 times more likely to develop a postoperative neurological deficit;

alternatively, for every 1 mL of blood loss; there was a 0.007% increase in the chance of developing a postoperative neurological deficit. Use of IONM during surgery has some potential for predicted worsening post-operative neurological outcomes, but no statistically significant (OR, 0.103; 95% CI, 0.008 – 1.298; $P=0.079$). On the other hand, BMI, age, gender, underlying disease, duration of symptoms, anatomical location, clinical presentation, extent of resection, type of operation, and recurrence were not associated with postoperative neurological outcomes.

Table 3. Multiple logistic regression analysis predicted for worsening post-operative neurological outcomes.

Factors	OR	95%CI	P-value
Body mass index	0.546	(0.281–1.060)	0.074
Age	1.010	(0.938–1.087)	0.796
Clinical presentation			
Pain	0.208	(0.010–4.175)	0.305
Motor	0.472	(0.007–30.945)	0.725
Sensory	0.228	(0.004–14.785)	0.487
Intraoperative neurophysiology monitoring	0.103	(0.008–1.298)	0.079
Anatomical location			
T12-L1	9.750	(0.599–158.664)	0.110
Cauda	9.714	(0.770–122.505)	0.079
Underlying disease			
Hypertension	0.848	(0.049–14.663)	0.910
Other	1.311	(0.075–22.848)	0.853
Instruments	1.778	(0.144–21.915)	0.653
Tumor size (millimeter)	0.997	(0.918–1.082)	0.938
Number of levels			
1	0.207	(0.017–2.503)	0.215
2	2.063	(0.166–25.677)	0.574
>2	4.625	(0.339–63.068)	0.251
Duration of symptom (months)	1.004	(0.939–1.073)	0.915
<24	2.778	(0.021–3.652)	0.330
>24	3.600	(0.274–47.333)	0.330
Operative time (hours)	2.629	(1.164–5.936)	0.020
Blood loss (milliliter)	1.007	(1.001–1.013)	0.026
Blood transfusion (unit)			
None	0.069	(0.005–0.913)	0.042
1-2	14.400	(1.095–189.332)	0.042

Discussion

Schwannomas are slow-growing benign tumors of the peripheral nervous system that originate from Schwann cells. This study aimed to describe the neurological outcomes of microsurgery and identify the factors associated with postoperative neurological deficits in patients with SS. According to the literature, no significant difference in the prevalence of SS between males and females was observed; furthermore, the disease was most prevalent during the fourth and fifth decades of life.⁽⁵⁻⁷⁾ Up to 80.0% of all SS are reported to be intradural/extramedullary lesions, and approximately 15.0% of all SS appear as a dumbbell-shaped mass with both intra- and extradural lesions.^(8,9) In the present study, 81.8% of the intraspinal schwannomas and 9.0% of dumbbell-shaped tumors were found in this study and correlate with other literature. Intramedullary lesions have been rarely reported in the literature, and none of the patients in the present study presented with these lesions.^(5,9) A significant improvement in neurological outcomes was observed before and after the surgery (Figure 1, Table 2). In the era of microsurgery, the surgeon can clearly see the tumor and the nerve or spinal cord interface, meticulously dissect the tumor from the neural structure, and safely remove it without causing any further neural tissue damage. The microsurgical technique is widely accepted for the management of various spinal tumors in order to reduce iatrogenic neural damage and minimize the incision size, which in turn reduces blood loss and muscle injury.^(10,11) This technique was used on all the patients in the present study.

Operative time, intraoperative blood loss, and blood transfusion factors were found to be associated with poor neurological outcomes in this study. A prolonged operation time usually indicates that the tumors are more difficult to remove. Massive blood loss indicates that the tumor is likely to have a large number of blood vessels or is malignant, making it very difficult to remove the tumor. Blood loss during surgery increases the likelihood of nerve or spinal cord ischemia, resulting in a poor surgical outcome. Therefore, to achieve good results, the operative time should be reduced and the blood loss during surgery should be minimized; this can be achieved by an experienced and well-trained surgeon.

Safae M, *et al.* reported that there was no difference in the use of IONM when comparing cases

with surgical complications and those without (67.0% vs. 69.0%, $P = 0.797$).⁽⁹⁾ However, the use of IONM was associated with a significantly higher rate of gross-total resection ($P = 0.022$).⁽⁹⁾ In this cohort, the author also found that use of IONM during surgery had some potential for predicted worsening postoperative neurological outcomes, but no statistically significant (OR, 0.103; 95% CI, 0.008 - 1.298; $P = 0.079$). Although determining the true effect of IONM in predicting postoperative neurological outcomes was not possible from the retrospective of this cohort.

Several studies have reported that STR is associated with a higher rate of tumor recurrence.^(4,12,13) Klekamp J, *et al.* reported that the recurrence rate of STR was 10.7% after five years in patients without NF2.⁽¹³⁾ Similar findings were observed in the present study, wherein five patients (11.4%) presented with STR and three (6.8%) with tumor recurrence. Total resection cannot be performed when there is adhesion or inflammation of the pia layer due to intratumoral bleeding prior to surgery that attached to important structure such as brachial plexus and conus medullaris and when the tumor originates directly from the ventral root and cannot be cut, despite the use of a microscope. The recurrent tumors in this study originated from residual tumors at the ventral root and need to be re-operated owing to the presence of progressive symptoms.

This study has several limitations, however. For example, it was a retrospective study with a limited number of patients; thus, we could not control for missing data. The follow-up duration was only one year after surgery, but the recurrence rate increased with time and postoperative instability was observed as a late-stage complication. This study was performed in a single institute, and the surgical approach used may lead to selection bias. In the case of the STR, adjuvant therapies such as radiosurgery appear to offer better results in preventing recurrence; nonetheless, this phenomenon needs to be further investigated in the future. Moreover, there were several uncontrollable factors such as complications from anesthesia. Additional studies focusing on the molecular aspects are required because the behaviors of tumors could vary based on their specific molecular profiles. Thus, distinct risk factors might be associated with tumor recurrence.

Conclusion

SS may occur at any levels on the spine and are typically intradural in location. The most common symptom of patients with SS is pain. Microsurgery resulted in a significant improvement in postoperative neurological outcomes among the patients in this study. Furthermore, intraoperative blood loss and operative time were found to be associated with postoperative neurological deficits.

Acknowledgements

The author thanks all subjects who contributed to this study and all staff members at the Vajira Center of Excellence in Neurosurgery, Department of Surgery, Faculty of Medicine Vajira Hospital in Bangkok, Thailand for their contribution.

Conflicts of interest statement

The authors have each completed an ICMJE disclosure form. None of the authors declare any potential or actual relationship, activity, or interest related to the content of this article.

Data sharing statement

The present review is based on the references cited. Further details, opinions, and interpretation are available from the corresponding authors on reasonable request.

References

1. Seppälä MT, Haltia MJ, Sankila RJ, Jääskeläinen JE, Heiskanen O. Long-term outcome after removal of spinal schwannoma: a clinicopathological study of 187 cases. *J Neurosurg* 1995;83:621-6.
2. Li P, Zhao F, Zhang J, Wang Z, Wang X, Wang B, et al. Clinical features of spinal schwannomas in 65 patients with schwannomatosis compared with 831 with solitary schwannomas and 102 with neurofibromatosis type 2: a retrospective study at a single institution. *J Neurosurg Spine* 2016;24:145-54.
3. Hirano K, Imagama S, Sato K, Kato F, Yukawa Y, Yoshihara H, et al. Primary spinal cord tumors: review of 678 surgically treated patients in Japan. A multicenter study. *Eur Spine J* 2012;21:2019-26.
4. Conti P, Pansini G, Mouchaty H, Capuano C, Conti R. Spinal neurinomas: retrospective analysis and long-term outcome of 179 consecutively operated cases and review of the literature. *Surg Neurol* 2004;61:34-43.
5. Jeon JH, Hwang HS, Jeong JH, Park SH, Moon JG, Kim CH. Spinal Schwannoma; analysis of 40 cases. *J Korean Neurosurg Soc* 2008;43:135-8.
6. Ohnishi Y, Iwatsuki K, Ohkawa T, Ninomiya K, Moriwaki T, Yoshimine T. Differences between cervical schwannomas of the anterior and posterior nerve roots in relation to the incidence of postoperative radicular dysfunction. *Asian Spine J* 2015;9:263-70.
7. Zou F, Guan Y, Jiang J, Lu F, Chen W, Xia X, et al. Factors affecting postoperative neurological deficits after nerve root resection for the treatment of spinal Intradural schwannomas. *Spine (Phila Pa 1976)* 2016;41:384-9.
8. Emel E, Abdallah A, Sofuoglu OE, Ofluoglu AE, Gunes M, Guler B, et al. Long-term surgical treatment outcomes of spinal schwannomas: retrospective analysis of 49 consecutively operated cases. *Turk Neurosurg* 2017;27:217-25.
9. Safaee M, Parsa AT, Barbaro NM, Chou D, Mummaneni PV, Weinstein PR, et al. Association of tumor location, extent of resection, and neurofibromatosis status with clinical outcomes for 221 spinal nerve sheath tumors. *Neurosurg Focus* 2015;39:E5.
10. Taylor H, McGregor AH, Medhi-Zadeh S, Richards S, Kahn N, Zadeh JA, et al. The impact of self-retaining retractors on the paraspinal muscles during posterior spinal surgery. *Spine* 2002;27:2758-62.
11. Teli M, Lovi A, Brayda-Bruno M, Zagra A, Corriero A, Giudici F, et al. Higher risk of dural tears and recurrent herniation with lumbar micro-endoscopic discectomy. *Eur Spine J* 2010;19:443-50.
12. Celli P. Treatment of relevant nerve roots involved in nerve sheath tumors: removal or preservation? *Neurosurgery* 2002;51:684-92.
13. Klekamp J, Samii M. Surgery of spinal nerve sheath tumors with special reference to neurofibromatosis. *Neurosurgery* 1998;42:279-89.